

CASE REPORT

Treatment of Bimaxillary Protrusion with Lever-Arm Mechanics and Micro-Implant Anchorage

RYOON-KI HONG, DDS, PHD
SEUNG-MIN LIM, DDS
JUNG-MIN HEO, DDS
JANG-HOON AHN, DDS, MSD, PHD

Bimaxillary protrusion is most commonly seen in African-American and Asian populations, although it can be found in almost every ethnic group.¹⁻³ Traditional treatment alternatives involve either orthodontics alone or anterior segmental osteotomy.

The dentoalveolar effects of conventional orthodontic treatment are retraction and retroclination of the upper and lower incisors, with a resultant reduction in soft-tissue procumbency and convexity. For bimaxillary-protrusion patients with proclined

upper and lower incisors, therefore, orthodontic treatment can produce the best facial esthetics without compromising dental esthetics, stability, or function. On the other hand, in a patient with relatively normal upper-incisor inclination and a gummy smile, anterior segmental osteotomy can be a better choice for resolving the lip protrusion without causing unwanted changes in upper-incisor inclination and exposure.

This article describes a new alternative: a lever-arm/micro-

implant (LA-MI) system used in treatment of a bimaxillary-protrusion patient with normal upper-incisor inclination and excessive upper-incisor exposure.

Diagnosis

A 24-year-old female presented with concerns about her convex profile. She exhibited excessive gingival display in smiling, a square jaw, and facial asymmetry in the frontal view (Fig. 1). The patient had bilateral Class II canine and molar rela-



Dr. Hong



Dr. Lim



Dr. Heo



Dr. Ahn

Dr. Hong is Chairman, Department of Orthodontics, Chong-A Dental Hospital, and Clinical Professor, Department of Orthodontics, School of Dentistry, Seoul National University, Seoul, Korea. Drs. Lim and Heo are in the private practice of orthodontics in Seoul. Dr. Heo is also a Clinical Professor, Department of Dentistry, College of Medicine, Hallym University, Chuncheon, Korea. Dr. Ahn is an Associate Professor, Department of Orthodontics, Kangnam Sacred Heart Hospital, Hallym University, Seoul. E-mail Dr. Hong at kloahong@naver.com.

Treatment of Bimaxillary Protrusion with Lever-Arm Mechanics

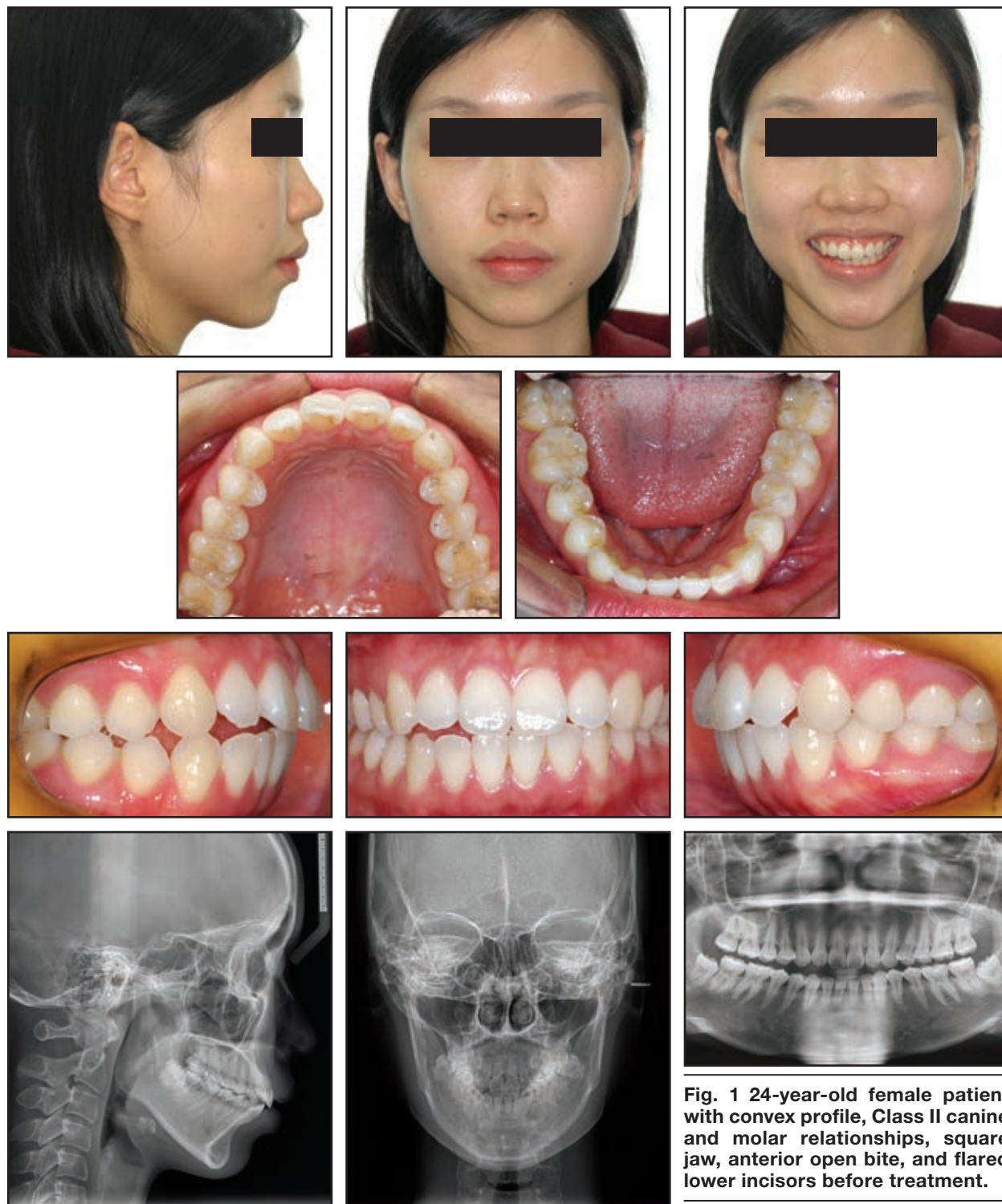

Fig. 1 24-year-old female patient with convex profile, Class II canine and molar relationships, square jaw, anterior open bite, and flared lower incisors before treatment.

TABLE 1
CEPHALOMETRIC ANALYSIS

	Norm	Pre-treatment	Post-Treatment	12-Month-Follow-up
SNA	81.6°	84.1°	82.4°	82.2°
SNB	79.2°	77.6°	77.1°	77.0°
ANB	2.5°	6.4°	5.3°	5.2°
FMA	24.3°	30.8°	31.0°	30.8°
NPo-FH	89.1°	84.4°	84.9	84.3°
Overbite	1.8mm	1.0mm	1.4mm	1.7mm
Overjet	3.5mm	1.8mm	1.9mm	1.5mm
1-FH	116.0°	115.1°	107.9°	108.8°
FMIA	59.8°	43.0°	58.0°	59.8°
Interincisal angle	123.8°	107.9°	133.1°	131.1°
Is-Is*	31.9mm	35.0mm	31.0mm	31.5mm
Upper lip to E-line	-0.9mm	3.0mm	-1.0mm	-1.0mm
Lower lip to E-line	0.6mm	5.0mm	-1.0mm	-1.2mm

*Distance from incisal edge of upper central incisor to palatal plane.

tionships, with a 1mm overbite, a 1.8mm overjet, an open bite in the right anterior region, and a 1.3mm arch-length discrepancy in the maxillary arch. She had been taking methimazole for two years to treat hyperthyroidism.

Cephalometric evaluation showed a skeletal Class II relationship with normally inclined upper incisors and flared lower incisors (Table 1). The panoramic radiograph indicated bone hyper trophy over the mandibular angle.

Treatment Plan

Our overall goals were to improve the patient's profile and smile esthetics and to achieve a harmonious occlusion. Treatment objectives were to correct the lip protrusion, reduce the excessive gingival display, and create a normal anterior and posterior occlusal relationship.

Because the patient did not want surgery for correction of the facial asymmetry, two other treatment options were discussed: a combination of traditional orthodontics and anterior segmental osteotomy, or extraction of the four first premolars followed by orthodontic retraction of the anterior dentition with micro-implant skeletal anchorage. The potential drawback of the second alternative is that patients with dentoalveolar protrusion usually present with thin and elongated anterior alveoli and/or bony defects, so that pushing the tooth against the thin cortical bone may cause root resorption or alveolar bone defects.⁴⁻⁶ In addition, excessive root movement can lead to root resorption and dehiscence of the labial or palatal cortical plate.⁷ Anterior segmental osteotomy is sometimes recommended to avoid these side effects, but it carries the risk of

postoperative complications such as ischemic necrosis of the anterior segment, wound dehiscence at the osteotomy site, or devitalization of the teeth adjacent to the osteotomy.⁸ After a review of the risks and benefits of these two options, the patient chose the more conservative method.

Because the patient requested esthetic orthodontic appliances, we decided to place lingual brackets in the upper arch and labial brackets in the lower. Lever arms and skeletal anchorage would be used for bodily retraction of the maxillary anterior teeth.

Treatment Progress

Eight days after extraction of the upper and lower first premolars, Fujita* lingual brackets

*Distributed in Korea by Kwang Myung DAICOM, Inc., Seoul, Korea; www.km2804.com.

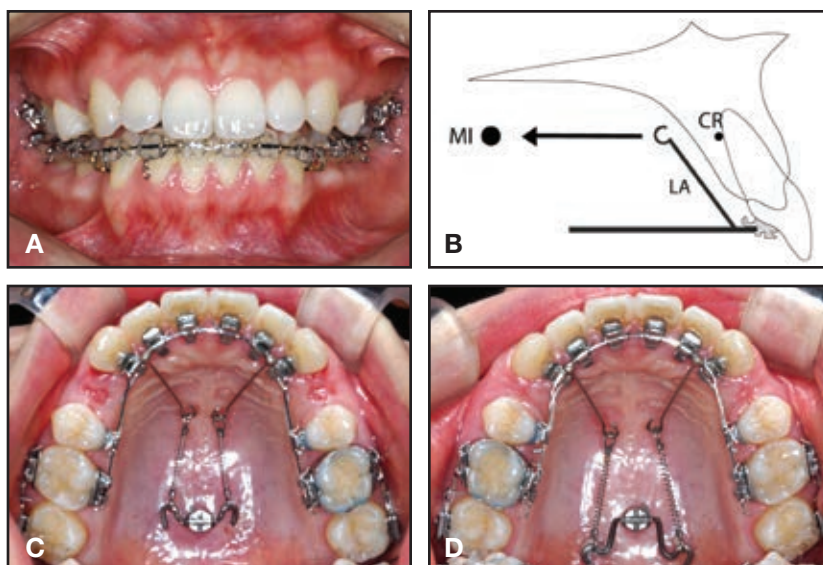


Fig. 2 A. After four months of treatment, .018" x .018" stainless steel mushroom closing archwire placed in upper arch and .016" x .022" stainless steel closing archwire in lower arch to begin en masse retraction. B. Lever-arm (LA) and micro-implant (MI) system designed to achieve bodily retraction of anterior teeth without anchorage loss: retraction force passes through center of resistance (CR) of anterior segment, parallel to occlusal plane. C. .028" stainless steel lever arms soldered to lingual mushroom archwire between lateral incisors and canines; SMS** micro-implant inserted in midpalatal suture at intersection with imaginary line between upper first molars; short .032" x .032" TMA*** power arms affixed to micro-implant head; nickel titanium closed-coil springs activated between power arms and lever arms. D. After six months of anterior retraction, new power arms attached to micro-implant head to increase activation.

were bonded indirectly in the maxillary arch,⁹ and an .012" nickel titanium mushroom archwire was engaged. In the mandibular arch, .018" preadjusted edgewise brackets were bonded directly, and an .014" nickel titanium archwire was placed. Leveling and alignment were performed with progressive archwire changes. To correct the open bite in the right anterior region, clear buttons were bonded to the upper right lateral incisor and canine, and vertical elastics (1/4", 4oz) were worn.

**BioMaterials Korea Inc., Seoul, Korea; www.biomaterialskorea.com.

***Registered trademark of Ormco Corporation, Orange, CA; www.ormco.com.

Four months into treatment, an .018" x .018" stainless steel mushroom closing archwire and an .016" x .022" stainless steel closing archwire were placed in the upper and lower arches, respectively, to begin en masse retraction (Fig. 2A). To achieve bodily retraction of the upper anterior teeth without anchorage loss, the LA-MI system was designed to apply a retraction force parallel to the occlusal plane and through the center of resistance of the anterior segment (Fig. 2B). Lever arms of .028" stainless steel wire were soldered to the lingual mushroom archwire between the lateral incisors and canines (Fig. 2C). An SMS** micro-implant was insert-

ed into the midpalatal suture in the region where it intersected an imaginary line between the upper first molars.¹⁰ Short power arms were fabricated from .032" x .032" TMA*** wire and affixed to the micro-implant head with ligature wire. Nickel titanium closed-coil springs were then attached between the power arms and .028" lever arms, with a force magnitude of 250g per side. After six months of anterior retraction, longer power arms were attached to the micro-implant head to increase the activation distance (Fig. 2D). During the final six months of retraction, vertical elastics (3/16", 4oz) were prescribed for interarch settling (Fig. 3).

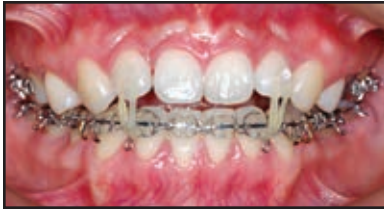

Fig. 3 Upper anterior teeth intruded spontaneously during bodily retraction, likely due to stiffness of mushroom closing archwire. Vertical elastics were prescribed during final six months of retraction for inter-arch settling.

The appliances and micro-implant were removed after a total 22 months of treatment. A wraparound removable retainer was delivered for the maxillary arch, and an .0175" multistranded stainless steel lingual retainer wire was bonded from second premolar to second premolar in the mandibular arch.

Treatment Results

The patient's convex profile and gummy smile were resolved, and an unexpected improvement in the square jaw was also observed (Fig. 4A). A Class I occlusion was achieved, with proper overbite and overjet and coincident maxillary and mandibular dental midlines. Moderate root resorption of the upper and lower incisors was seen in the panoramic radiograph.

The overall superimposition of cephalometric tracings showed favorable lingual retrusion of the upper and lower lips, along with minor skeletal changes (Fig. 4B, Table 1). The maxillary regional superimposition confirmed bodi-

ly retraction and retrusion of the incisors, with no protraction of the molars (Fig. 4C). Controlled tipping of the incisors and a slight mesial movement of the molars could be seen in the mandibular superimposition.

One year later, the occlusion, smile esthetics, and profile had been maintained, but the correction of the square jaw had not (Fig. 5).

Discussion

When the six maxillary anterior teeth are retracted in a premolar-extraction case, the applied moment-to-force ratio determines the type of tooth movement—whether uncontrolled tipping, controlled tipping, bodily movement, or root thrusting. Therefore, the application point and direction of the retraction force in relation to the center of resistance are critical factors for the clinician in predicting and planning esthetic movement of the anterior teeth.

Many techniques have been introduced to control movement of the upper incisors by using the width and depth of the palate.¹¹⁻¹³ Chung and colleagues' C-retractor and C-plate rely on segmented lever-arm mechanics and do not require brackets on the maxillary teeth, but tend to cause anterior torque loss and tipping and intrusion of the maxillary canines.^{11,12} To solve these problems, the C-retractor is removed from the canine area after en masse retraction, and the finishing phase is started by placing an .022" × .028" preadjusted fixed appliance on the entire maxillary arch. In

contrast, the continuous lever-arm mechanics used in our patient allowed the anterior teeth to be retracted bodily and guided along the dental arch without any vertical bowing effects.¹³

Spontaneous intrusion of the upper incisors contributed to the correction of our patient's gummy smile without the need for additional micro-implants (Fig. 3). It seems likely that the stiff .018" × .018" stainless steel mushroom closing archwire guided the distal movement of the anterior teeth parallel to the occlusal plane, so that the anterior teeth were intruded as they were retracted. Because the degree of upper-incisor intrusion will vary depending on the steepness of the occlusal plane, the upper-incisor display must be considered when designing the LA-MI system. In this case, we were able to achieve bodily retraction and simultaneous intrusion of the upper anterior teeth without anchorage loss, correcting the convex profile and gummy smile of a bimaxillary-protrusion patient with normally inclined upper incisors—a situation that has previously been addressed with anterior segmental osteotomy.¹⁴

If the orthodontic tooth movement and alveolar bone remodeling occur in a 1:1 ratio, the tooth will remain in the alveolar housing, known as tooth movement "with the bone".¹⁵ If a proper balance between resorption and apposition of the alveolar bone is not established, however, the tooth will move out of the alveolar housing—"through the bone".¹⁶ In Class I patients with

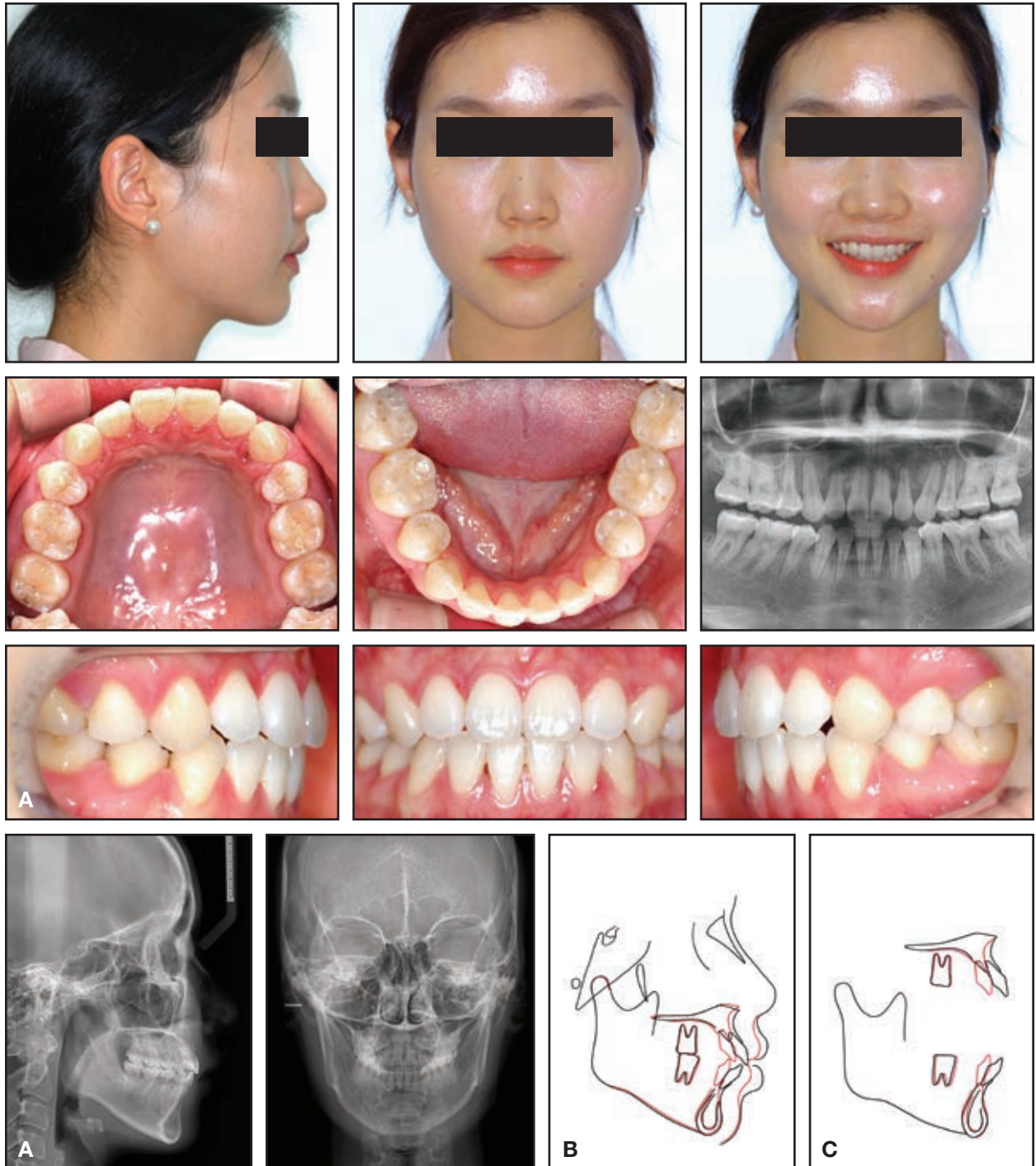


Fig. 4 A. Patient after 22 months of treatment. B. Superimposition of pre- and post-treatment cephalometric tracings on SN at sella. C. Regional superimpositions of pre- and post-treatment cephalometric tracings on palatal plane at ANS and on mandibular plane at menton.

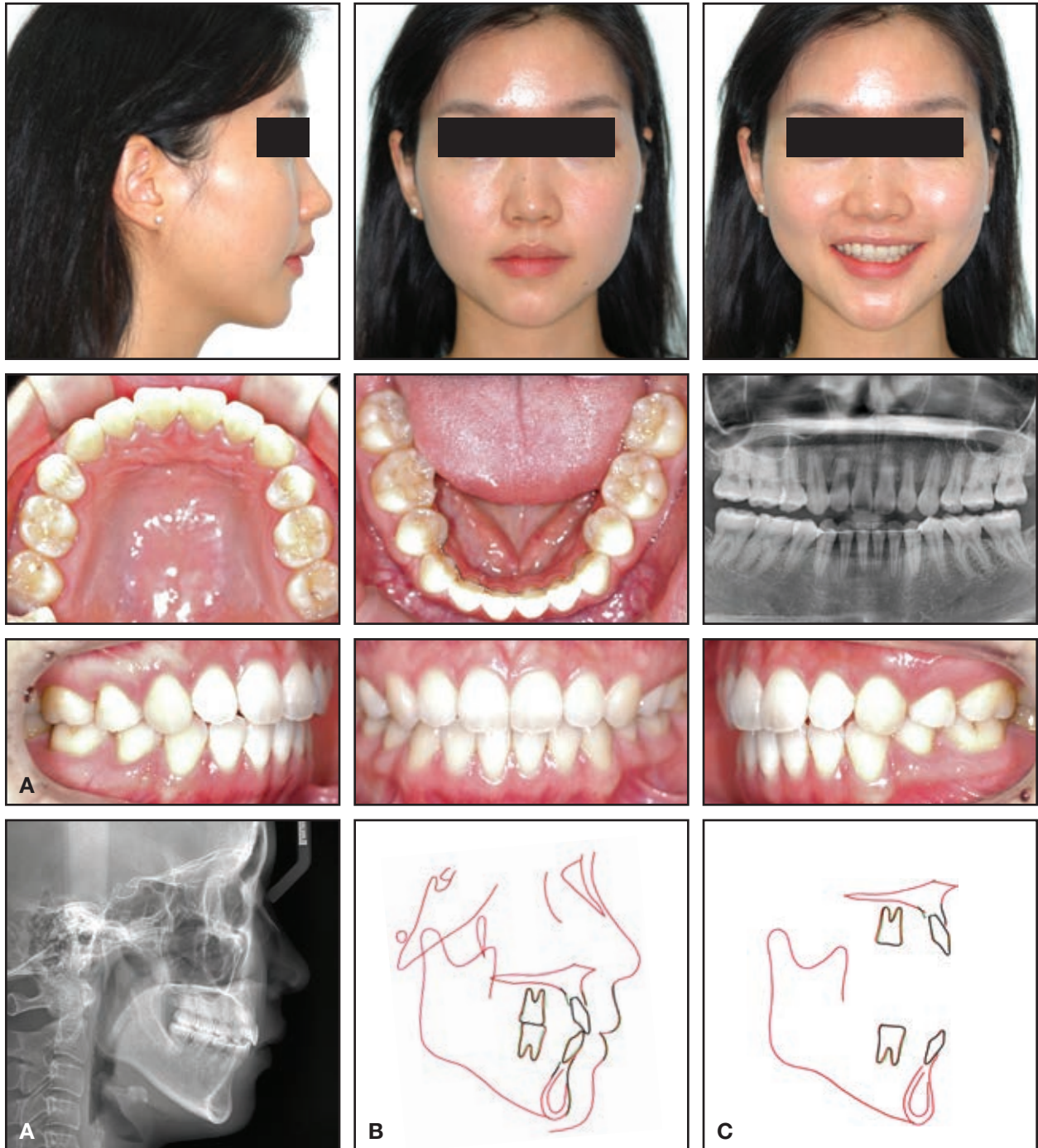


Fig. 5 A. Patient one year after debonding. Square jaw improved spontaneously during treatment, but did not remain stable. B. Superimposition of post-treatment (red) and follow-up (green) cephalometric tracings on SN at sella. C. Regional superimpositions of post-treatment (red) and follow-up (green) cephalometric tracings on palatal plane at ANS and on mandibular plane at menton.

bimaxillary protrusion, en masse retraction of the maxillary anterior teeth with maximum anchorage can result in tooth movement through the bone. The anatomical limits set by the cortical plates of the alveolus at the level of the incisor apices act as barriers to incisor retraction, causing side effects such as bone loss and apical root resorption.^{17,18} Previous studies have shown that once the cortical plate has been penetrated by the root, the well-defined dense cortical plate will not recover.¹⁹⁻²¹ In our patient, since the roots of the maxillary incisors were retracted through the palatal cortical plate, the treatment mechanics may have led to iatrogenic root resorption.

A square jaw is the result of masseter hypertrophy and/or excessive development of the mandibular angle.²² Corrective measures include resection of the mandibular angle, surgical reduction of the masseter muscle, and intramuscular injection of botulinum toxin type A. In the present case, even though the patient exhibited bone hypertrophy over the mandibular angle, the square jaw improved spontaneously during treatment. This unexpected improvement, which we have often observed in bimaxillary-protrusion cases, may be attributable to masseter muscle hypotrophy caused by a reduction in masticatory forces during orthodontic treatment.

Conclusion

The LA-MI system for bodily retraction of the upper incisors can be an effective treatment alter-

native in a bimaxillary-protrusion patient with normally inclined upper incisors and a gummy smile. It is minimally invasive, usually requiring only one palatal mini-implant for skeletal anchorage.

REFERENCES

- Farrow, A.L.; Zarrinnia, K.; and Azizi, K.: Bimaxillary protrusion in black Americans—An esthetic evaluation and the treatment considerations, *Am. J. Orthod.* 104:240-250, 1993.
- Rosa, R.A. and Arvystas, M.G.: An epidemiologic survey of malocclusions among American Negroes and American Hispanics, *Am. J. Orthod.* 73:258-273, 1978.
- Tan, T.J.: Profile changes following orthodontic correction of bimaxillary protrusion with a preadjusted edgewise appliance, *Int. J. Adult Orthod. Orthog. Surg.* 11:239-251, 1996.
- Sarikaya, S.; Haydar, B.; Ciğer, S.; and Ariyürek, M.: Changes in alveolar bone thickness due to retraction of anterior teeth, *Am. J. Orthod.* 122:15-26, 2002.
- Vardimon, A.D.; Oren, E.; and Ben-Bassat, Y.: Cortical bone remodeling/tooth movement ratio during maxillary incisor retraction with tip versus torque movements, *Am. J. Orthod.* 114:520-529, 1998.
- Nahm, K.Y.; Kang, J.H.; Moon, S.C.; Choi, Y.S.; Kook, Y.A.; Kim, S.H.; and Huang, J.: Alveolar bone loss around incisors in Class I bidentoalveolar protrusion patients: A retrospective three-dimensional cone beam computed tomography study, *Dentomaxillofac. Radiol.* 41:481-488, 2012.
- Wehrbein, H.; Fuhrmann, R.A.; and Diedrich, P.R.: Periodontal conditions after facial root tipping and palatal root torque of incisors, *Am. J. Orthod.* 106:455-462, 1994.
- Scheideman, G.B.; Kawamura, H.; Finn, R.A.; and Bell, W.H.: Wound healing after anterior and posterior subapical osteotomy, *J. Oral Maxillofac. Surg.* 43:408-416, 1985.
- Hong, R.K.; Kim, Y.H.; and Park, J.Y.: A new customized lingual indirect bonding system, *J. Clin. Orthod.* 34:456-460, 2000.
- Hong, R.K.; Lim, S.M.; Heo, J.M.; and Baek, S.H.: Lingual applications of the midpalatal absolute anchorage system, *J. Clin. Orthod.* 46:344-353, 2012.
- Chung, K.R.; Kook, Y.A.; Kim, S.H.; Mo, S.S.; and Jung, J.A.: Class II malocclusion treated by combining a lingual retractor and a palatal plate, *Am. J. Orthod.* 133:112-123, 2008.
- Chung, K.R.; Jeong, D.M.; Park, H.J.; Kim, S.H.; and Nelson, G.: Severe bidentoalveolar protrusion treated with lingual biocreative therapy using palatal miniplate, *Kor. J. Orthod.* 40:276-287, 2010.
- Hong, R.K.; Heo, J.M.; and Ha, Y.K.: Lever-arm and mini-implant system for anterior torque control during retraction in lingual orthodontic treatment, *Angle Orthod.* 75:129-141, 2005.
- Lee, J.K.; Chung, K.R.; and Baek, S.H.: Treatment outcomes of orthodontic treatment, corticotomy-assisted orthodontic treatment, and anterior segmental osteotomy for bimaxillary dentoalveolar protrusion, *Plast. Reconstr. Surg.* 120:1027-1036, 2007.
- Melsen, B.: Biological reaction of alveolar bone to orthodontic tooth movement, *Angle Orthod.* 69:151-158, 1999.
- Verna, C.; Zaffe, D.; and Siciliani, G.: Histomorphometric study of bone reactions during orthodontic tooth movement in rats, *Bone* 24:371-379, 1999.
- Ahn, H.W.; Moon, S.C.; and Baek, S.H.: Morphometric evaluation of changes in the alveolar bone and roots of the maxillary anterior teeth before and after en masse retraction using cone-beam computed tomography, *Angle Orthod.* 83:212-221, 2013.
- Handelman, C.S.: The anterior alveolus: Its importance in limiting orthodontic treatment and its influence on the occurrence of iatrogenic sequelae, *Angle Orthod.* 66:95-109, 1996.
- Wainwright, W.M.: Faciolingual tooth movement: Its influence on the root and cortical plate, *Am. J. Orthod.* 64:278-302, 1973.
- Sarikaya, S.; Haydar, B.; Ciğer, S.; and Ariyürek, M.: Changes in alveolar bone thickness due to retraction of anterior teeth, *Am. J. Orthod.* 122:15-26, 2002.
- Rommelink, H.J. and van der Molen, A.L.: Effects of anteroposterior incisor repositioning on the root and cortical plate: A follow-up study, *J. Clin. Orthod.* 18:42-49, 1984.
- Hashimoto, T.; Kuroda, S.; Kamioka, H.; Mishima, K.; Sugahara, T.; and Takano-Yamamoto, T.: Bimaxillary protrusion with masseter muscle hypertrophy treated with titanium screw anchorage and masseter surgical reduction, *Am. J. Orthod.* 135:536-548, 2009.